

Congenital temporomandibular joint ankylosis—a case report

Anna Komorowska

Department of Jaw Orthopaedics, Medical Academy of Lublin, Poland

SUMMARY A case of congenital temporomandibular joint (TMJ) ankylosis which caused facial disfigurement, significant reduction in mouth opening, difficulties in feeding and breathing, and general interference with physical and mental development is presented. The wide range of manifestations exceed the typical picture of TMJ ankylosis and resemble a syndrome rather than an isolated defect of the TMJ.

Introduction

Temporomandibular joint (TMJ) ankylosis most commonly occurs after trauma or infection (Topazian, 1964; Brady and Sanders, 1978). Congenital cases have been reported by Converse (1979) and Tideman and Doddridge (1987). They are so rare that they should be described in detail for better understanding of the disease. No publication up to the present time has been concerned with the longitudinal observation of a growing child with TMJ ankylosis. The aim of this paper is to present the course of the condition over a period of 7 years in a case of congenital TMJ ankylosis combined with many other manifestations which together may represent a new syndrome.

History

The patient, a female and the first child of young and healthy parents, was born prematurely after an uneventful pregnancy. She was in an incubator for the first 2 months of life because of respiratory disorders. At the age of 6 months, it was noticed that she exhibited significant restriction in mouth opening. At the same time, her mother observed a bird-face profile, when the child was in a sitting position. The child experienced two episodes of acute respiratory problems in the first 2 years of life which were probably bronchopneumonia and required hospitalization. Respiratory disorders were

present from infancy; the child slept in a semi-sitting position but still exhibited loud snoring and wheezing. Her feeding was characterized by an inability to masticate food, limiting intake to liquids or semi-liquids. The developmental stages of sitting independently, walking, and acquisition of first words were all achieved at the expected time. She was first seen in the Department of Jaw Orthopaedics, at the age of 4 years and 3 months, after her local paediatrician had referred her to several other specialists. By that time she had two younger siblings, both free of signs of similar problems.

Clinical examination

The clinical findings included short stature (98 cm) and low weight (15 kg) for her age. She exhibited noisy breathing even in an upright position. As an orthodontist is not an authority on general health conditions, the patient was referred to a children's hospital for detailed and thorough examination. The examination of her internal organs revealed no additional problems, but unfortunately no specific tests for hypoxia were carried out at the time of the first visit. On orthodontic examination, the frontal view of the face showed a severely retruded chin, narrow forehead, low-set ears, and some facial asymmetry with pogonion deviated to the right (Figure 1A). The patient exhibited a bird-like facial profile with retrognathia of the mandible, a double chin, and a relatively short neck (Figure

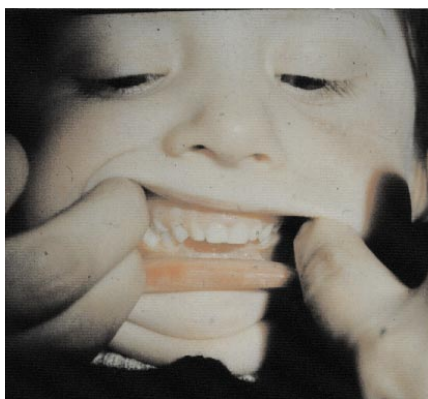
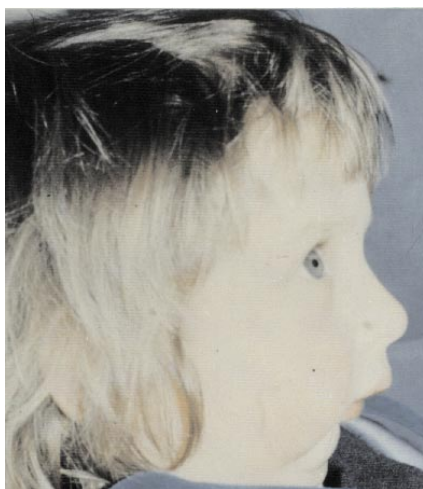
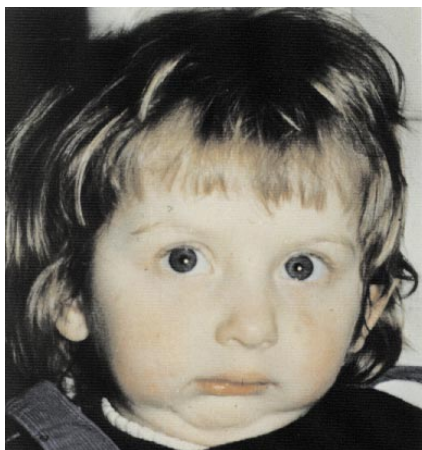Figure 1 Initial appearance of the patient: (A) frontal view; (B) profile; (C) intraoral view.

Table 1 Clinical symptoms found in the affected child.

History of trauma or infection	none
Mandible at birth	normal
Motion in TMJ at birth	normal
First visible restriction of mouth opening	at 6 months
Respiratory problems	from infancy, serious
Snoring	loudly
Wheezing	yes
Sleeping only in semi-sitting position	yes
Short stature	yes
Gradual mental retardation	yes

1B). She had a Class II division 1 malocclusion with a posterior crossbite on the right. Mouth closure was complete (Figure 1C). When a metal spatula was placed between the deciduous molars to force the teeth apart, the interincisal opening was 1 mm. Forward or lateral movements of the mandible were impossible. The set of clinical symptoms revealed in the patient are shown in Table 1.

Radiographic examination

A lateral head film showed unusual growth of the skull and jaws. The forehead was flat, the frontal sinuses were compressed horizontally, the parietal bones appeared thin while the occipital bones were thick, and the bony contour adjacent to the lambdoid suture was prominent. The cranial base angle was abnormally obtuse due to a depressed position of sella and elevated position of nasion. This abnormality meant that other standard measurements related to the sella–nasion line would be false. Marked enlargement of the angle ANB was mainly caused by the severe retrusion of the mandible. Mandibular size and shape showed significant deviation from age-appropriate norms. The mandibular body was small, and the distance between gnathion and gonion was nearly half of its normal length. The mandibular rami were extremely small, and there was abnormal curvature of the gonial region which was further emphasized by marked depression of the

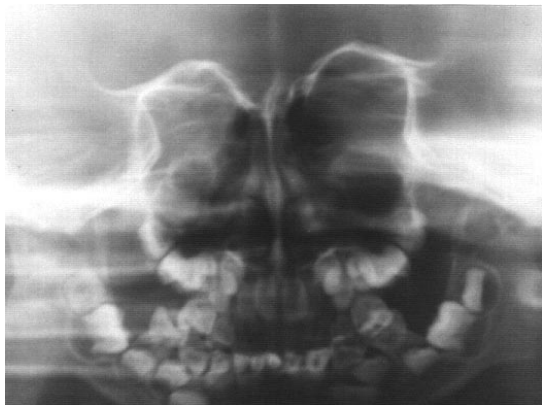
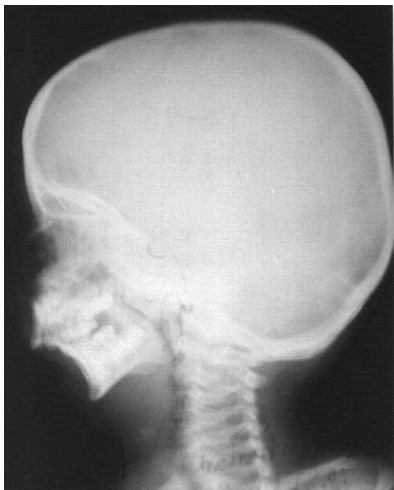

Figure 2 Roentgenographic images: (A) cephalometric roentgenograph in lateral projection; (B) panoramic radiograph.

antegonial notch. The facial skeleton appeared relatively small in comparison with the neurocranium and there was midface retrusion. The upper airway was severely restricted and the pharyngeal depth markedly reduced (Figure 2A).

The panorex radiograph revealed the condyles to be short and underdeveloped bilaterally. On the right, the condyle was fused with the glenoid fossa and the surface of the condylar head was hidden by bony masses. The left condyle was compressed tightly to the glenoid fossa, but the outline of the condylar head remained visible as a separate structure. Germs of second lower

Table 2 Radiographic symptoms found in the affected child.

Unusual growth of the skull and jaws	yes
Unequal thickness of skull bones	yes
Abnormally obtuse cranial base angle	yes
Frontal sinuses compressed horizontally	yes
Small mandibular body and rami with marked depression of antegonial notch	yes
Retrognathia	severe
Reduced pharyngeal depth	severe

Table 3 Course of the condition during the observation period.

Age	Event
4 years 3 months	myotherapy
6 years	cor pulmonale tracheostomy
6 years 2 months	condylectomy
7 years 6 months	eruption of first molars
7 years 10 months	eruption of lower incisors
9 years	eruption of upper incisors
10 years 10 months	second condylectomy

molars were located just below the sigmoid notch, distal to the gonial angle (Figure 2B). On axial CT scans, the right TMJ was more affected and higher in position than the left, presumably an indication of primary involvement of the right side which was followed by secondary immobilization of the opposite side. The radiographic symptoms are shown in Table 2.

Course of the condition

The patient's progress was followed over a period of 7 years (Table 3). At the beginning, muscle exercises were proposed to increase mobility of the mandible. To stimulate normal mastication, chewing on a small rubber tube was recommended (Figure 3A). To encourage anterior movement, an oral screen was used (Figure 3B). Results were promising and the range of mouth opening reached 5 mm. However, this amount of opening was achieved with constriction of the suprahyoid muscle and visible tension of the depressor labii inferioris (Figure 3C). No more progress was obtained and

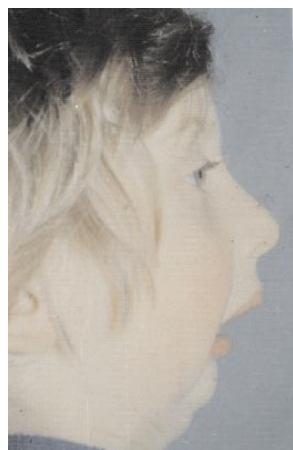
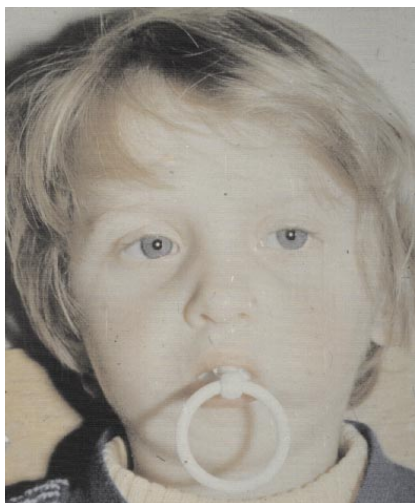
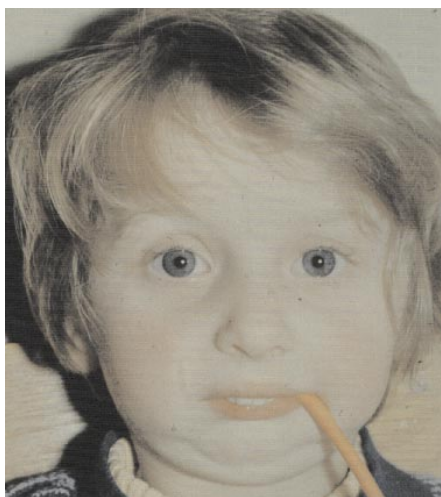Figure 3 Photographs taken after intensive myotherapy: (A) exercise with rubber tube; (B) oral screen *in situ*; (C) mouth opening.

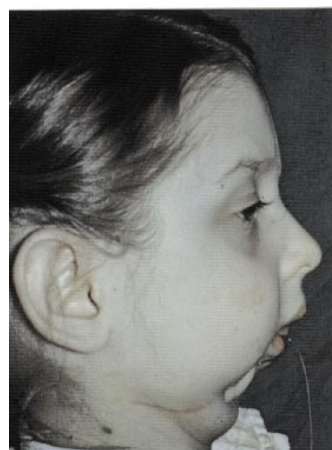
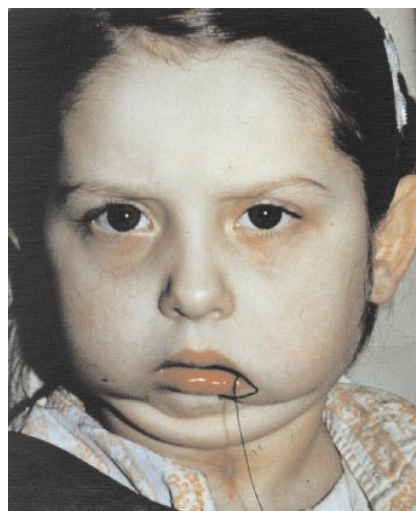
Figure 4 The frontal (A) and right lateral (B) photographs taken 3 weeks post-operatively.

after a few months of intensive muscle therapy the patient ceased regular visits. She returned to our department only as a result of an immediate need for medical help. She was wheezing loudly, her lips and fingernails were cyanosed, and generalized oedema was visible. Her mother reported that the child had slept excessively and gained weight rapidly due to fluid retention just prior to this episode. A tracheostomy was performed as a life-saving procedure. She was examined thoroughly for the second time by a paediatrician, cardiologist, neurologist and ENT specialist. A diagnosis of cor pulmonale was

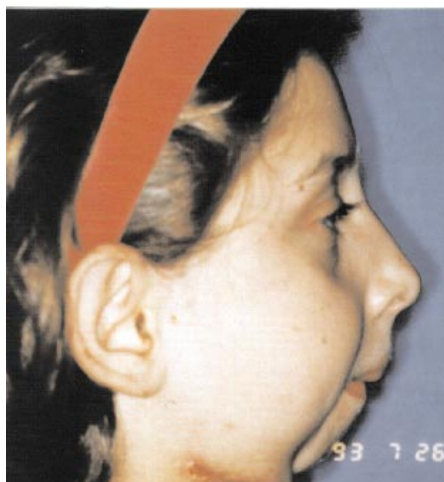
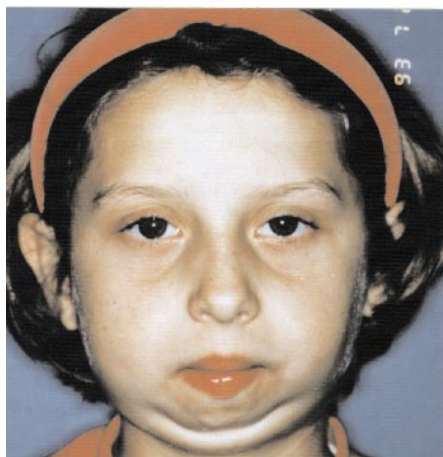

Figure 5 The facial appearance after the second condylectomy: (A) frontal view; (B) profile.

established. Two months later, a bilateral low condylectomy was performed. On return for physiotherapy to the orthodontic department, the patient presented a stable open bite of 13 mm and was unable to close her mouth after keeping a piece of cork between the dental arches for 3 weeks, as recommended by the maxillo-facial surgeon. Frontal and lateral photographs taken at that time are shown in Figure 4A and B. A modified monobloc appliance was designed to move the mandible forward as much as possible. After 6 months, mouth closing was achieved

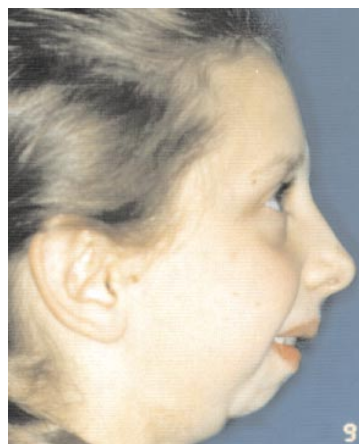
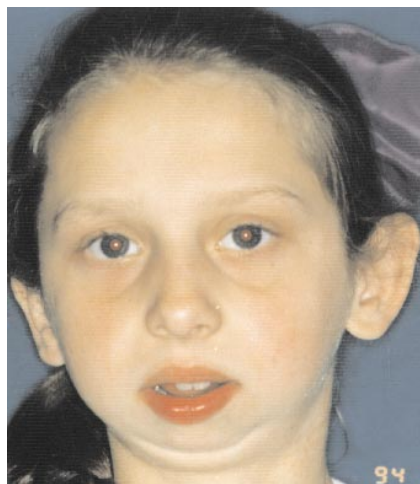
Figure 6 Frontal (A) and lateral (B) views after 10 months of post-operative orthodontic treatment.

without reduction in the range of opening. The patient wore the appliance almost full time, since it gave her a sense of security due to improved ability to breathe. Eruption of the permanent incisors decreased the interincisal gap and further use of the appliance eventually became impossible. At the age of 10 years and 10 months, a second condylectomy was necessary due to increasing breathing problems. This operation opened the bite to 28 mm anteriorly. Post-operative views of the patient are shown in Figure 5A and B. A new activator with a

progressive construction bite was fabricated to stimulate gradual forward movement of the mandible. When she was seen at the age of 11 years and 8 months, the patient had achieved improved facial symmetry (Figure 6A). In spite of the functional treatment, growth of the surgically released portion of the mandible was insufficient and a convex profile was evident (Figure 6B). Prolonged inadequate nutrition, impaired breathing and generalized hypoxia probably contributed to a handicapped physical and mental development, primarily originating from the nature of the condition. At this time, the patient remains short (132 cm) and of low weight (24.1 kg) for her age (11 years and 8 months). Her general intelligence index tested by WISC (Wechsler test for children 5–15) increased from 68 at the beginning of observation to 78 during a recent examination, which is below normal limits.

Discussion and conclusions

The case is considered to represent a true congenital ankylosis of the TMJ as no causative factor could be identified in the history. The possibility of infection may be excluded because the infant was isolated in an aseptic environment immediately after delivery. Furthermore, neonatal onset of severe respiratory disorders is a strong indication of a congenital defect. The fact that the restriction in mouth opening was not observed until 6 months of age does not eliminate a diagnosis of congenital defect as some mobility of the mandible even in congenital ankylosis has been observed prior to the time of fusion of the cranial sutures (Tideman and Doddridge, 1987; Zins *et al.*, 1989). The clinical picture of congenital TMJ ankylosis found in the literature is so typical that it should not be confused with other disorders. This includes difficulty or inability to open the mouth with all its consequences, and a bird-face appearance mainly in bilateral cases. A diagnosis of the congenital form is certain if a child is born with a significant restriction in mouth opening, but if ankylosis develops with time, aetiological

factors such as trauma or infection must be diagnosed prior to the recognition of acquired form. In the discussed case, the first symptoms of TMJ ankylosis were found only 6 months after birth without detecting any causes. Among the spectrum of clinical features, an unusual ossification of the cranium resulting in its abnormal shape and thickness of the bones, short stature and handicapped mental development indicate the presence of numerous defects of unknown aetiology. It seems very probable that it is a new variant of TMJ ankylosis, which resembles a syndrome rather than an isolated defect of the joint, and which has not so far been classified.

Detailed descriptions of clinical, functional and radiographic findings are necessary in order to establish a set of pathognomonic symptoms which can aid in the recognition of true congenital TMJ ankylosis combined with many other manifestations which together may represent a new syndrome.

Address for correspondence

Anna Komorowska
Department of Jaw Orthopaedics
Medical Academy of Lublin
Karmelicka 7 str.
20-081 Lublin
Poland

References

- Brady F, Sanders B 1978 Traumatic ankylosis of the temporomandibular joint. *Clinical Otolaryngology* 3: 127–132
- Converse J M 1979 Surgical release of bilateral, intractable, temporomandibular joint ankylosis. *Plastic and Reconstructive Surgery* 64: 404–407
- Tideman H, Doddridge M 1987 Temporomandibular joint ankylosis. *Australian Dental Journal* 3: 171–177
- Topazian R G 1964 Etiology of ankylosis of the temporomandibular joint. Analysis of 44 cases. *Journal of Oral Surgery, Anesthesia and Hospital Dentistry Services* 22: 227–233
- Zins J E, Smith J D, James D R 1989 Surgical correction of temporomandibular joint ankylosis. *Clinics in Plastic Surgery* 4: 725–731